

January - June 2022

Volume 31

Issue 1

PRINT ISSN: 2277-1867

ONLINE ISSN: 2277-8853



JOURNAL OF FORENSIC MEDICINE SCIENCE AND LAW

Official Publication of Medicolegal Association of Maharashtra

Editor-in-chief

Dr Ravindra Deokar

Associate Editors

Dr Sadanand Bhise

Dr Sachin Patil

**MULTISPECIALITY, MULTIDISCIPLINARY, NATIONAL
PEER REVIEWED, OPEN ACCESS, MLAM (SOCIETY) JOURNAL
Indexed with Scopus (Elsevier) & Index Copernicus (Poland)**

Editorial Office Address

Department of Forensic Medicine & Toxicology, Third Floor, Library Building, Seth G S Medical College & KEM Hospital, Parel, Mumbai, Maharashtra, India. Pin-400 012. Email id: mlameditor@gmail.com Phone: 022-24107620 Mobile No. +91-9423016325.



JOURNAL OF FORENSIC MEDICINE SCIENCE AND LAW

(Official Publication of Medicolegal Association of Maharashtra)

Email.id: mlameditor@gmail.com

PRINT ISSN:

2277-1867

ONLINE ISSN:

2277-8853

Case Report

Sexual Gratification in Lockdown

Kashif Ali^a, Mohd. Kaleem Khan^b

^aSenior Resident, ^bAssociate Professor, Department of Forensic Medicine, Jawaharlal Nehru Medical College, AMU, Aligarh (UP). Pin-202001.

Article Info

Received on: 03.05.2021

Accepted on: 30.05.2022

Key words

Foreign body,
Sexual gratification,
Rectum.

Abstract

Foreign objects introduced into rectum either for sexual gratification or by accident or as a result of assault or torture. Removing the foreign object is an emergency procedure and if not done in time can lead to dangerous complications. The case herein reported is that of a male with an alleged history of insertion of foreign object i.e., deodorant bottle in his rectum by himself for sexual gratification but the bottle slipped, and sucked into the rectum which was beyond his reach of grasp.

1. Introduction

Foreign body inserted into the rectum through the anal canal is usually to gain sexual pleasure and many at times it slips beyond the grasp of an individual and get lodged in the rectum or beyond it. Sexual gratification by an object is often achieved by self or with help of a partner. These objects may vary from beer bottles, cans, bulbs, cups, candles, vegetables, etc. Excess exposure to internet contents and developing of ideas of experimentation in sexual desires has brought society to the edge. Medical fraternity is supposed to deal with these sexual perversions and their physical and psychological consequences.

Sodomy though commonly practiced unnatural sex these days, got its name from city Sodom.¹ These days it is getting more attention due to liberalization of laws towards choice of sex and forming of same sex communities like LGBT and more. The foreign body when inserted in to the rectum of an individual with an intention to assault, it causes great physical trauma along with mental trauma and social stigma. Physical trauma and

depth of insertion in rectum or beyond it will lead to different method employed for extraction of the foreign body. The Indian penal code does not account for the mental pain and social embarrassment but physical trauma is dealt in section 319, 320, 302 IPC²⁻⁴ depending upon the delayed consequences of trauma intended. If simply removed without complications or hospital stay then tried for IPC 319, any hospitalization more than 20 days will attract Grievous hurt, further complications leading to death the perpetrator will be charged with murder (302 IPC).

2. Case Report

A male of 21 years of age was brought to the Emergency and Trauma section of J.N. Medical College, AMU, Aligarh at around 12:00 AM on 12th June 2020 with history of self-introduction of foreign body in rectum along with bleeding per anum. Further the patient told that he is a homosexual and is in same sex relationship from past 3 years. He was unable to reach out to his partner due to complete lockdown because of Corona pandemic.

How to cite this article: Ali K, Khan MK. Sexual Gratification in Lockdown. J For Med Sci Law 2022;31(1):105-107.

*Corresponding author: Dr. Mohd. Kaleem Khan, Associate Professor, Department of Forensic Medicine, Jawaharlal Nehru Medical College, AMU, Aligarh (UP), India. Email- drkaleemkhanfmt@gmail.com (M): +91-9997992459.

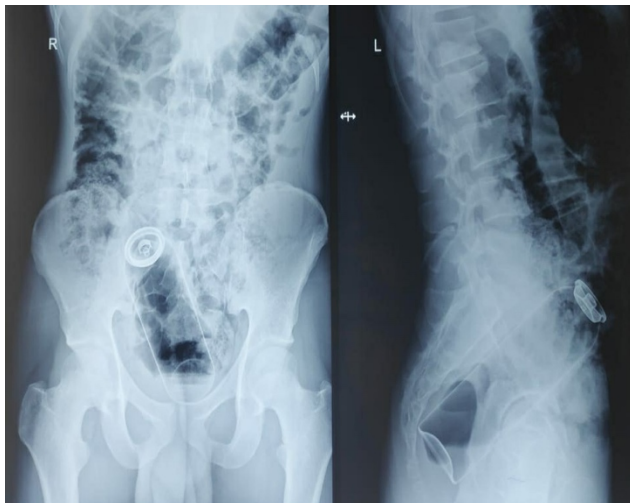
So due to paucity of source for sexual gratification he tried to get sexual satisfaction by inserting the deodorant bottle (Fig. 1) into his anus but the bottle slipped, and sucked into the rectum which was beyond his reach of grasp. After that pain and bleeding started.

There was bleeding from the anal canal. Abdomen was soft and non-tender and locally little bleeding was found in anal region with bruising of the perianal tissue. On Per rectal examination foreign body was found impacted above the dentate line in the anal canal. X-ray of pelvis (Fig. 2) showed well defined radio-opaque structure in the region of pelvis lying anterior to the sacrum and no gas under the diaphragm. Foreign body was removed per rectum under local anaesthesia, further fresh bleeding occurred after the removal of foreign body. Later course of patient was uneventful and patient was discharged eventually.

Fig. 1: Deodorant bottle (125 ml capacity) retrieved from rectum.



Fig. 2: X-ray of pelvis showing deodorant bottle in rectum



3. Discussion

The cases of impacted foreign body in rectum show patient as victim varying incidences in different part of the World tend not to disclose the actual history how it happened because of the embarrassment he may face in the society towards the incidence.⁵ Therefore the total number of cases which are reported may be lower than the actual number of cases. With a ratio of 37:1, a systematic review shows that the incidence of retained colorectal foreign body is disproportionately higher in men.⁶ At presentation, 90% of patients give inaccurate history, some reported to present with peritonitis and were not forthcoming even when facing life threatening situation.⁷⁻⁹ In most of the cases the foreign body can be extracted trans-anally, though some patients require anaesthesia for the management of the case. Patient usually come to the hospital when attempts of self-removal fails. For the classification of rectal organ injury, the use of a system for penetrating and blunt injuries created by the Association of American Trauma Surgery (AAST) is helpful for evaluation of rectal foreign objects.^{10,11}

AAST rectal organ injury scale-

- Grade 1: Contusion or haematoma (without devascularization and/or partial laceration)
- Grade 2: Laceration \leq 50%, peripheral
- Grade 3: Laceration \geq 50%, peripheral
- Grade 4: Full-thickness laceration extending to the perineum
- Grade 5: Devascularized segment

Section 377 IPC refers to unnatural offences and says whoever voluntarily has carnal intercourse against the order of nature with any man, woman or animal shall be punished with imprisonment for life or with imprisonment of either description for a term which may extend to 10 years and shall also be liable to pay a fine.¹² On 6th September 2018, the Supreme court of India unanimously ruled that section 377 IPC is unconstitutional as it infringed on the fundamental rights of intimacy, identity and autonomy thus legalizing homosexuality in India. The court explicitly overturned its 2013 judgement. This has passed way for more sexual choices and needs for sexual gratification.

4. Conclusion

While handling these types of cases of rectal foreign body impaction, the history should be taken carefully as there may be difference in the history given by the patient and family members. The cases

of foreign body insertion in rectum usually goes unreported to avoid social embarrassment. The management of such type of cases includes multi-disciplinary approach involving Radiologist, Surgeon, Psychiatrist and Forensic Medicine experts. It should be extracted by the operative procedure only when all attempts to remove it have been failed. After the treatment, patient should be counselled by the Psychiatrist and if any underlying mental illness is detected then it should be looked into.

To prevent homophobia or sexual prejudice against homosexuals in today's scenario is a tough task, so for this a positive approach towards their sexual orientation and addressing their problems linked to their homosexuality is the need of hour.

Contributor ship of Author: All authors have equally Contributed.

Conflict of interest: None.

External funding: Nil.

References

1. Aggrawal A. Chapter 25, Sexual Offences. In Textbook of Forensic Medicine and Toxicology. 1st Ed. Himachal Pradesh: Avichal Publishing Company; 2017. p.458.
2. Indian Penal Code (IPC), Section 319. Hurt. (Internet) [Cited on 29th October 2020] Available from <http://www.vakilno1.com/bareacts/IndianPenalCode/S319.htm>.
3. Indian Penal Code (IPC), Section 320. Grievous Hurt. (Internet) [Cited on 29th October 2020] Available from <http://www.vakilno1.com/bareacts/IndianPenalCode/S319.htm>.
4. Indian Penal Code (IPC), Section 302. Murder. (Internet) [Cited on 29th October 2020] Available from <http://www.vakilno1.com/bareacts/IndianPenalCode/S319.htm>.
5. Mohamad IS, Yaacob H. An Aubergine in case of rectal foreign body. Malays Fam Physician. 2018;13(3);47-48.
6. Kurer MA, Davey C, Khan S, Chintapatla S. Colorectal foreign bodies: A systematic review. Colorectal Dis. 2010;12(9):851-61.
7. Kokemohr P HL, Frömling FJ, Landwehr P, Jähne J. Surgical management of rectal foreign bodies:a 10-year single-center experience. Innov Surg Sci. 2017;2(2):89-95.
8. Cologne KG, Ault GT. Rectal foreign bodies: what is the current standard? Clin Colon Rectal Surg. 2012;25(4):214-8.
9. Cawich SO, Thomas DA, Mohammed F, Bobb NJ, Williams D, Naraynsingh V. A Management Algorithm for Retained Rectal Foreign Bodies. Am J Mens Health. 2017;11(3):684-92.
10. Cologne KG, Ault GT. Rectal foreign bodies: what is the current standard? Clin Colon Rectal Surg. 2012;25(4):214-8.
11. Moore EE, Cogbill TH, Malangoni MA, Jurkovich GJ, Champion HR, Gennarelli TA, et al. Organ injury scaling II: Pancreas, duodenum, small bowel, colon, and rectum. J Trauma. 1990;30(11):1427-9.
12. Indian Penal Code (IPC), Section 377. Unnatural Offences, (Internet) [Cited on 29th October 2020] Available from <http://www.vakilno1.com/bareacts/IndianPenalCode/S319.htm>